Case of the Month: November 2019

Dr. Sunil Pasricha

Consultant Pathology, RGCI&RC

Case History

- A 48-year-old male with complaints of haemoptysis and breathlessness for 5 months was **evaluated elsewhere**
- A PET-CT was performed which revealed right sided pleural effusion with metabolically active right pleural deposits (largest: 2.5cm), mediastinal & cervical lymph nodes. Right lobe of thyroid showed ill-defined hypodense lesion with heterogenous tracer uptake
- A working clinico-radiological diagnosis was Lung carcinoma (Stage IV)
- A pleural biopsy performed was reported as primary lung papillary adenocarcinoma

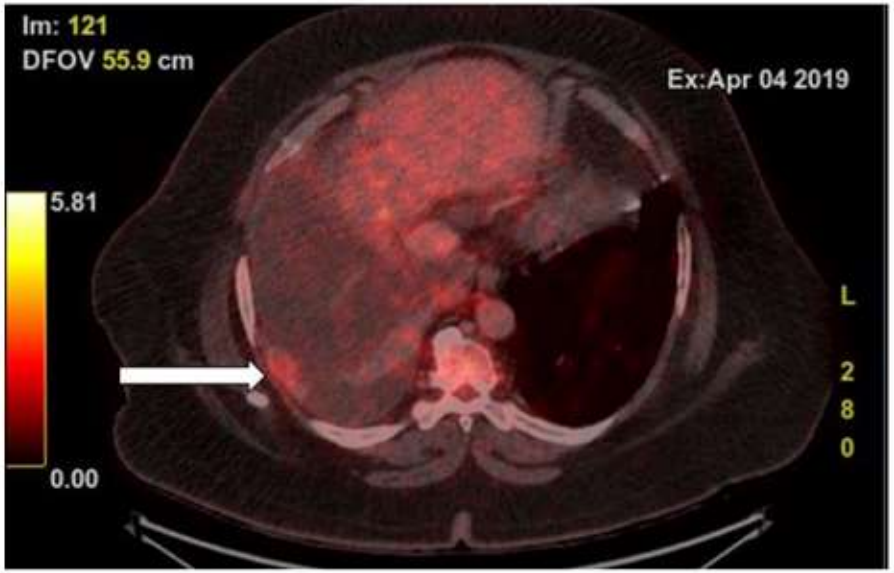

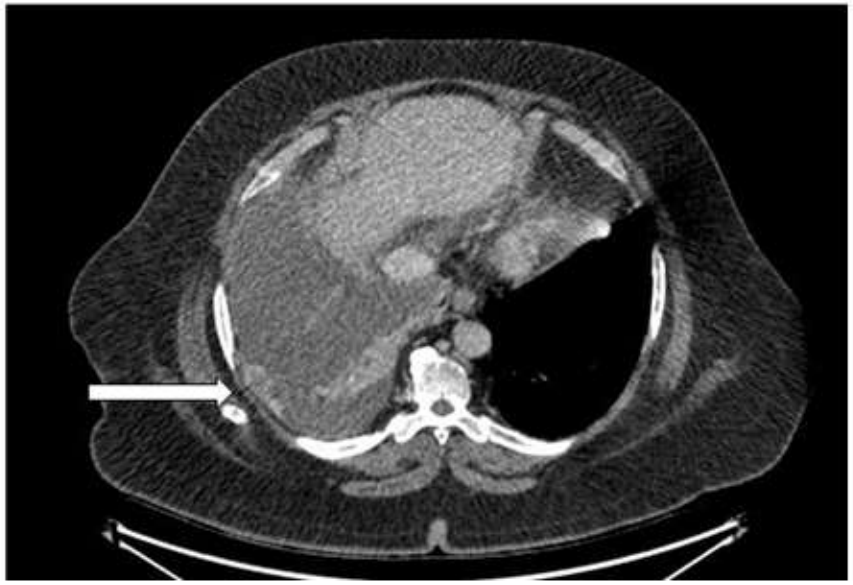

Figure: Axial CT images with contrast (read sequences –Fused PET-CT images and post contrast CT left to right). Heterogeneously enhancing nodular deposit (Arrows) seen in right pleural space with right pleural effusion.

- On further investigations, no driver mutations (EGFR/ROS1/ALK: Negative) were identified

- The patient subsequently presented to our Institute with respiratory symptoms and was started with 1st cycle of Pemetrexed & Carboplatin based chemotherapy

- Concomitantly, paraffin embedded biopsy blocks were sent for histopathological review and confirmation

Section shows fibrocollagenous tissue infiltrated by a tumor with Papillary pattern of growth

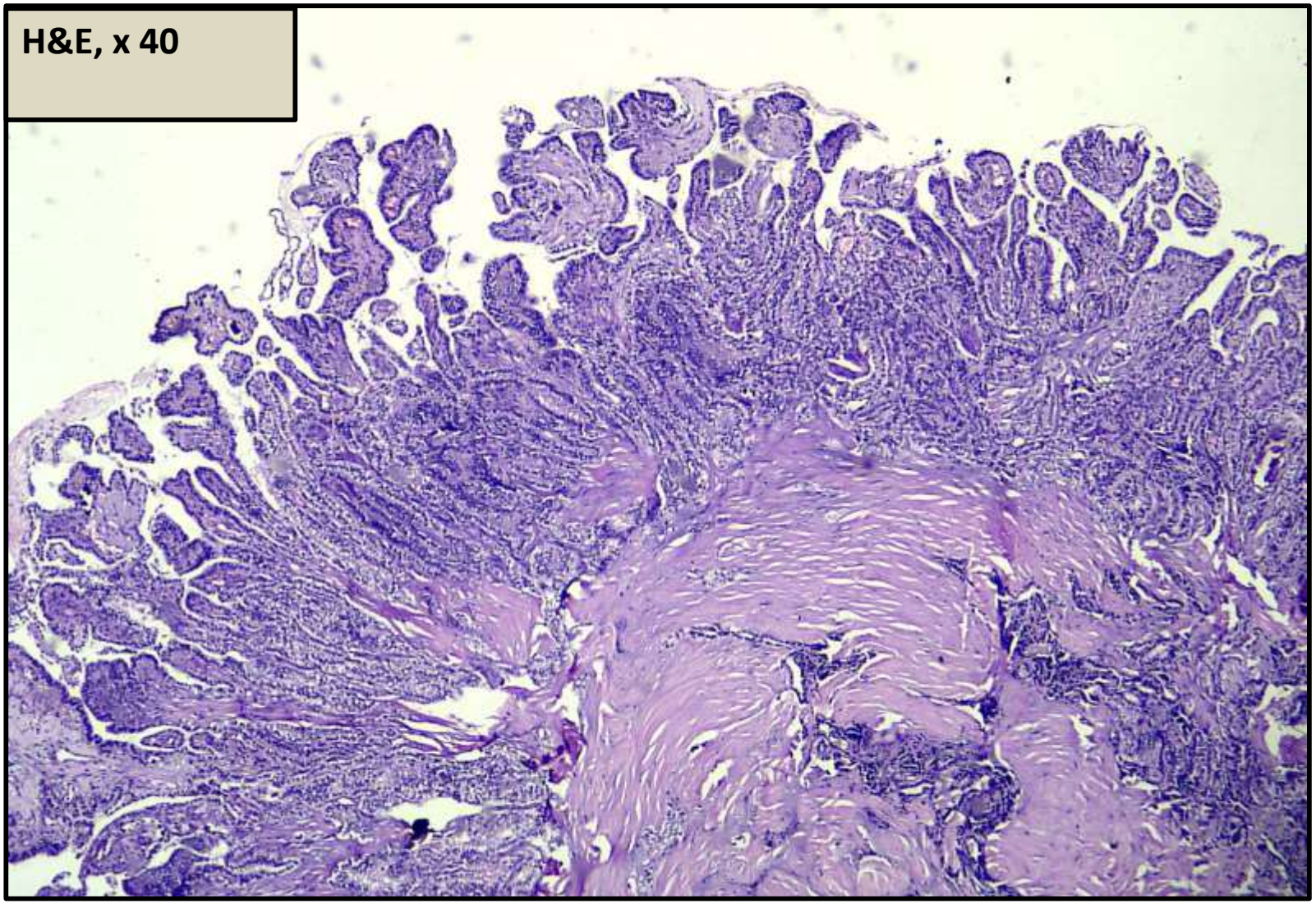

Section shows Papillae with fibrovascular cores and occasional psammoma body

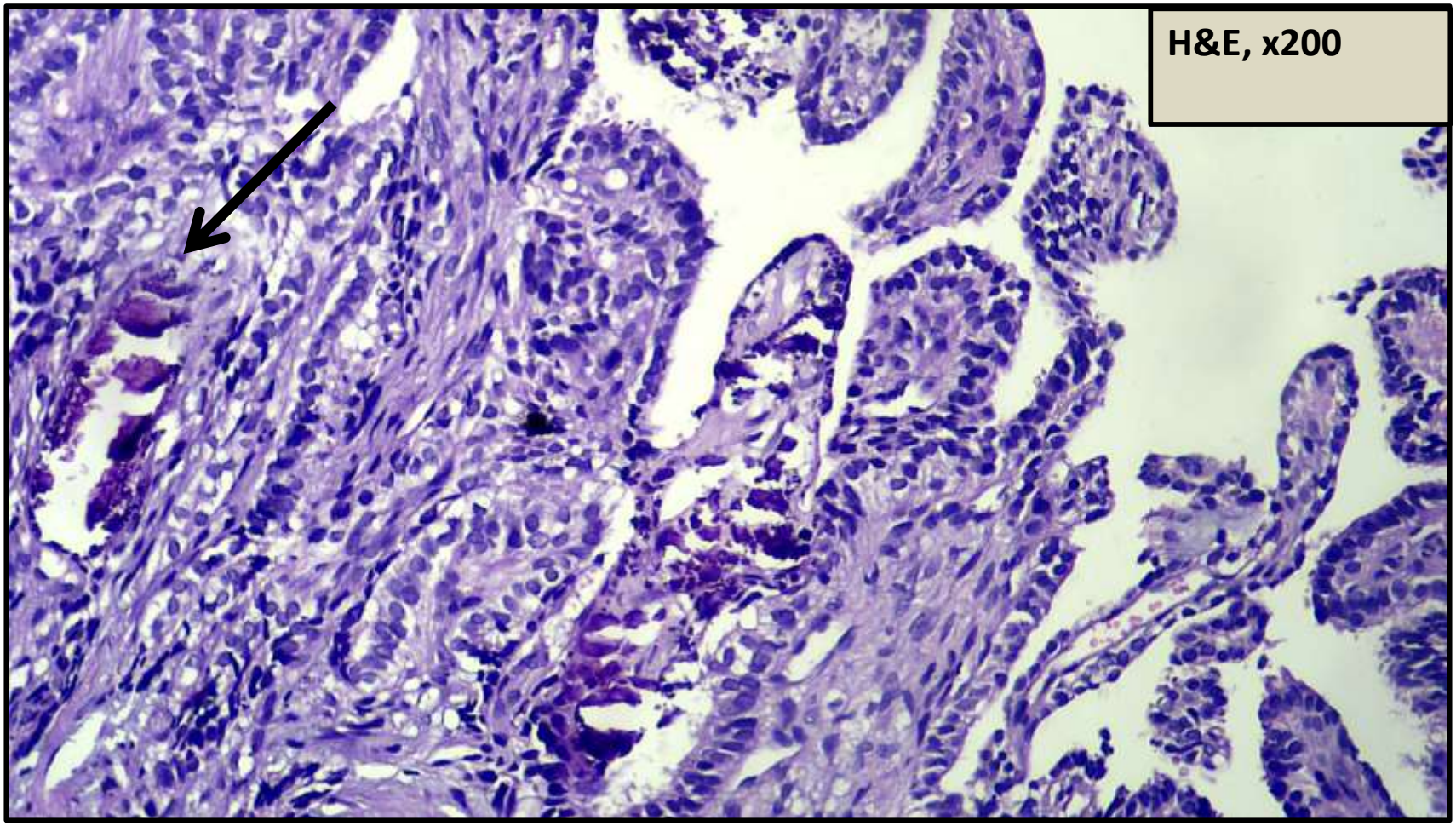

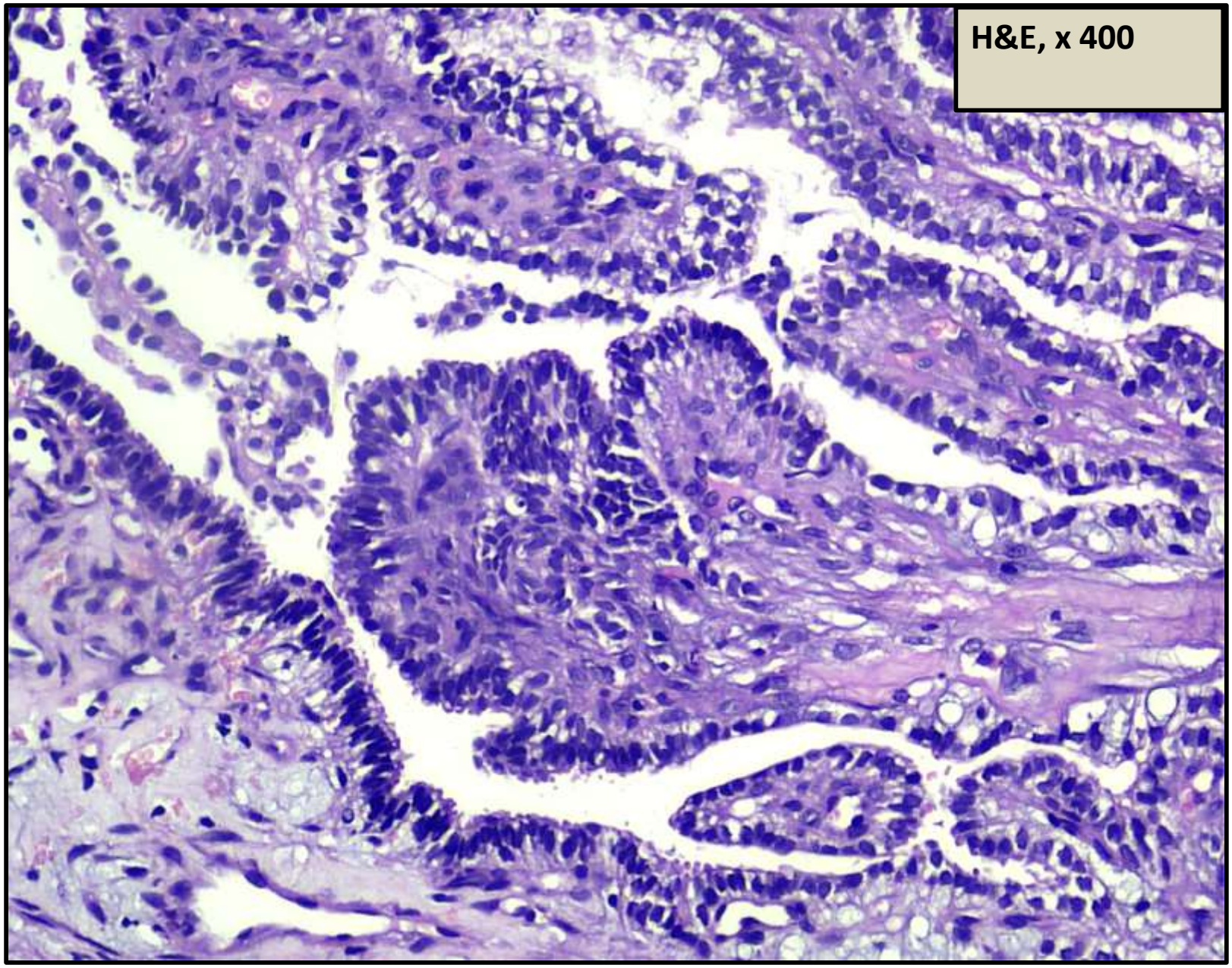
H&E, x 400

Summarizing the H/P findings

- Fibrocollagenous tissue infiltrated by a tumor with Papillary pattern of growth
- The nucleus are oval to elongated with inconspicuous nucleoli
- There is no evidence of high grade nuclear atypia/pleomorphism
- On further IHC the tumor cells were diffusely and strongly positive for TTF-1

TTF1

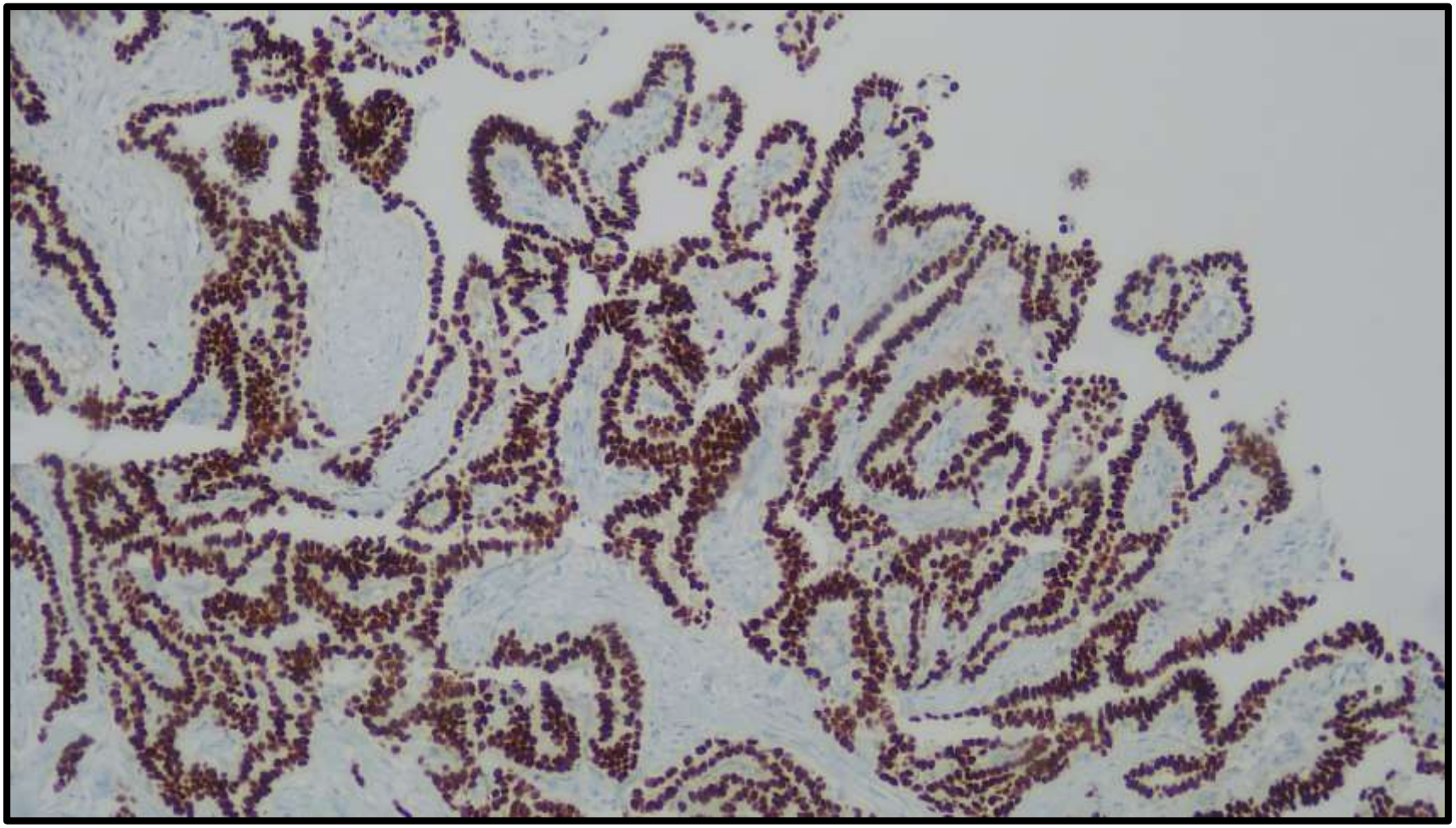

Histopathological Diagnosis as per WHO 2015 reporting protocol of small biopsy of lung

- Non small cell carcinoma: Adenocarcinoma
- Predominant Pattern of growth: Papillary
- Level of evidence: Morphological
- The IHC findings (TTF1 expression) were in resonance with the outside biopsy report of Lung Adenocarcinoma with papillary pattern of growth

- However, on diligent morphological assessment, presence of nuclear stratification, regimentation and psammoma bodies were evocative of metastatic deposit of Papillary Thyroid Carcinoma (PTC) and provoked us to rule out this remote possibility
- Subsequently IHC for PAX-8 and Thyroglobulin were given

PAX8

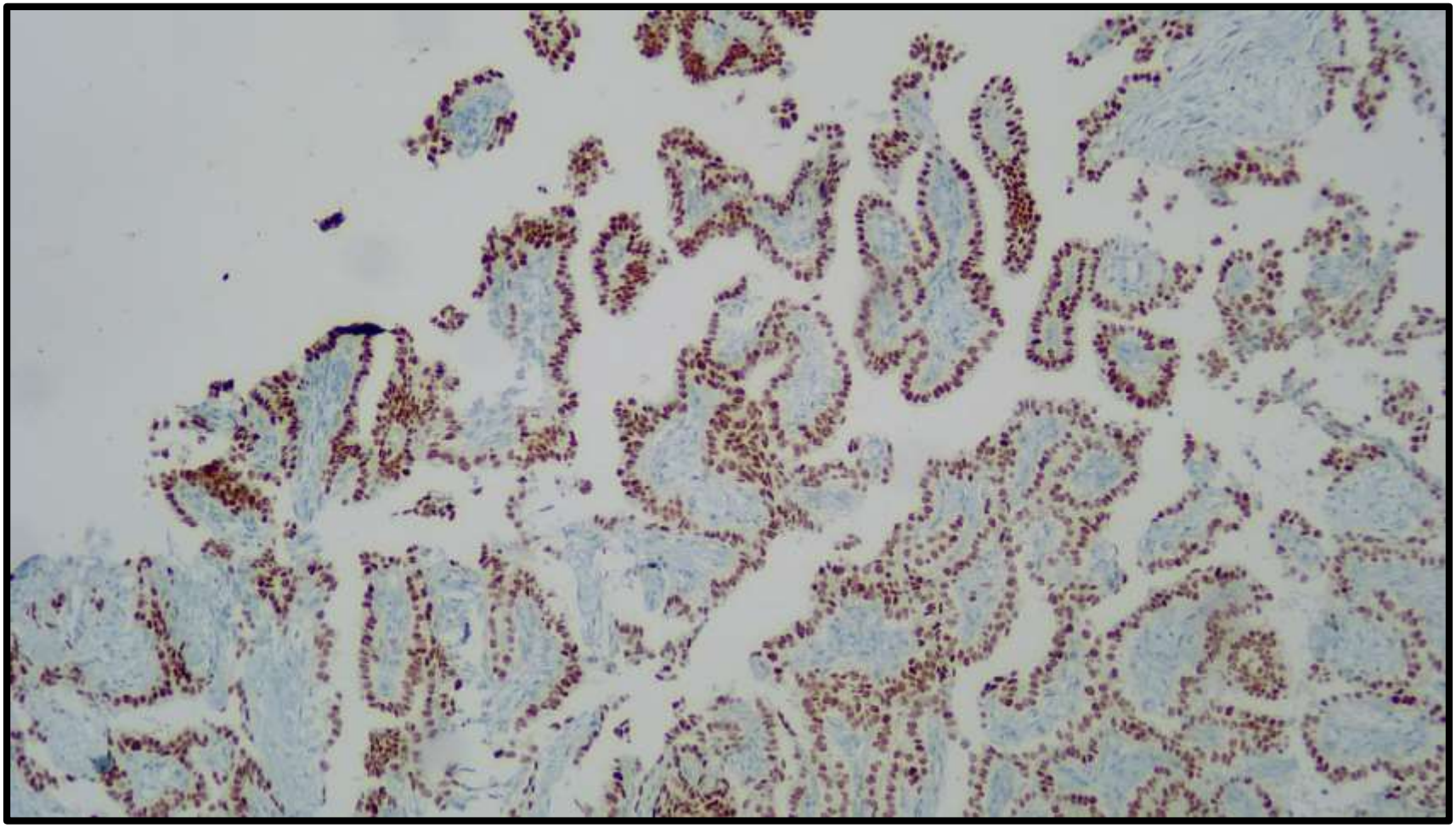

Thyroglobulin

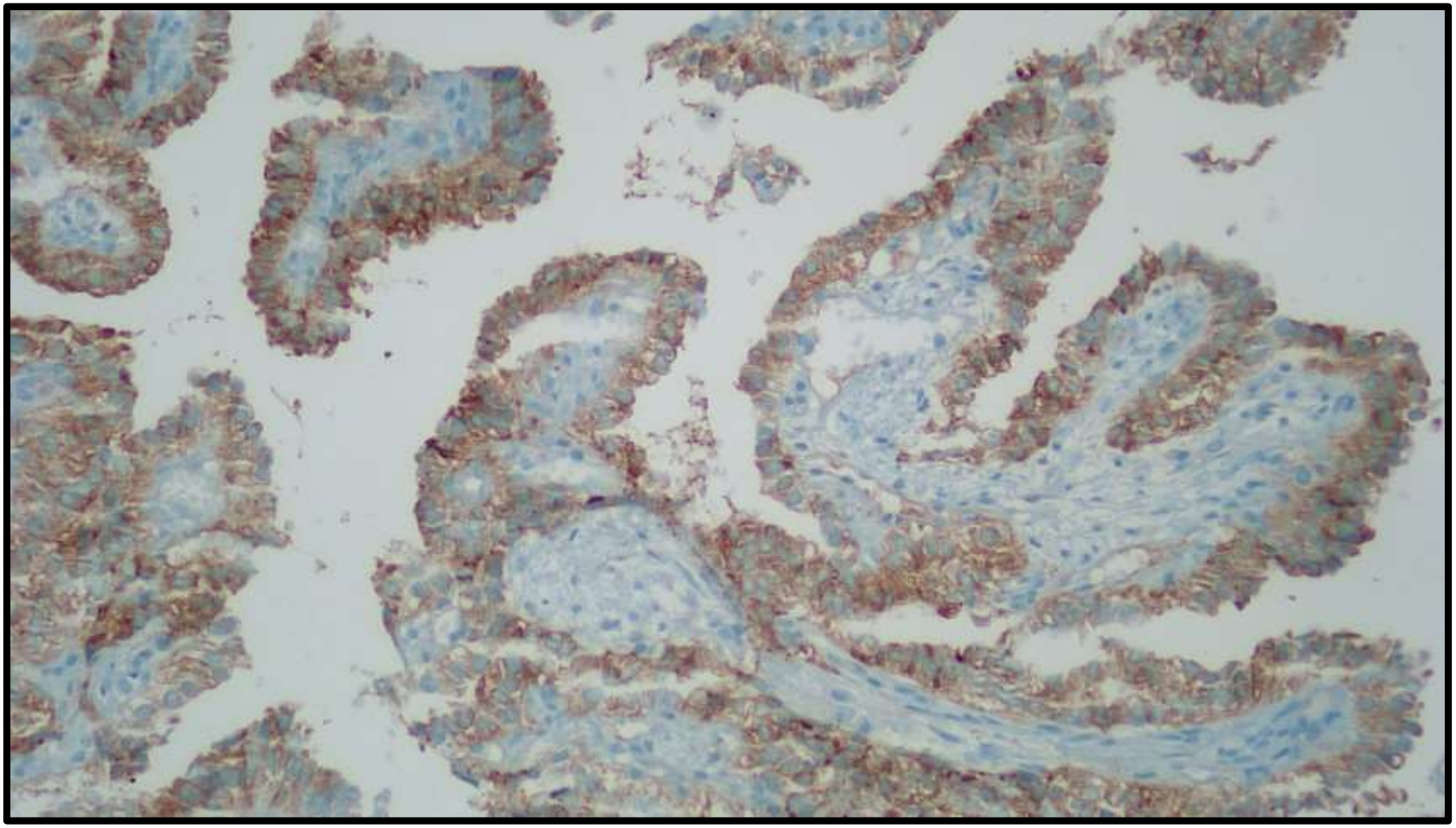

Final Diagnosis

- Metastatic tumor deposit of papillary thyroid carcinoma(PTC) revealing Occult primary
- The case was subsequently discussed in the multispeciality tumour board and PET scan was reviewed.
- The reviewed radiological findings were in resonance with histopathological diagnosis of metastatic PTC

Therapeutic Implications

- The ongoing Chemotherapy was withheld and the patient was planned for total thyroidectomy with bilateral selective neck dissection
- The specimen was recived in the Histopathology Lab

Right Lobe

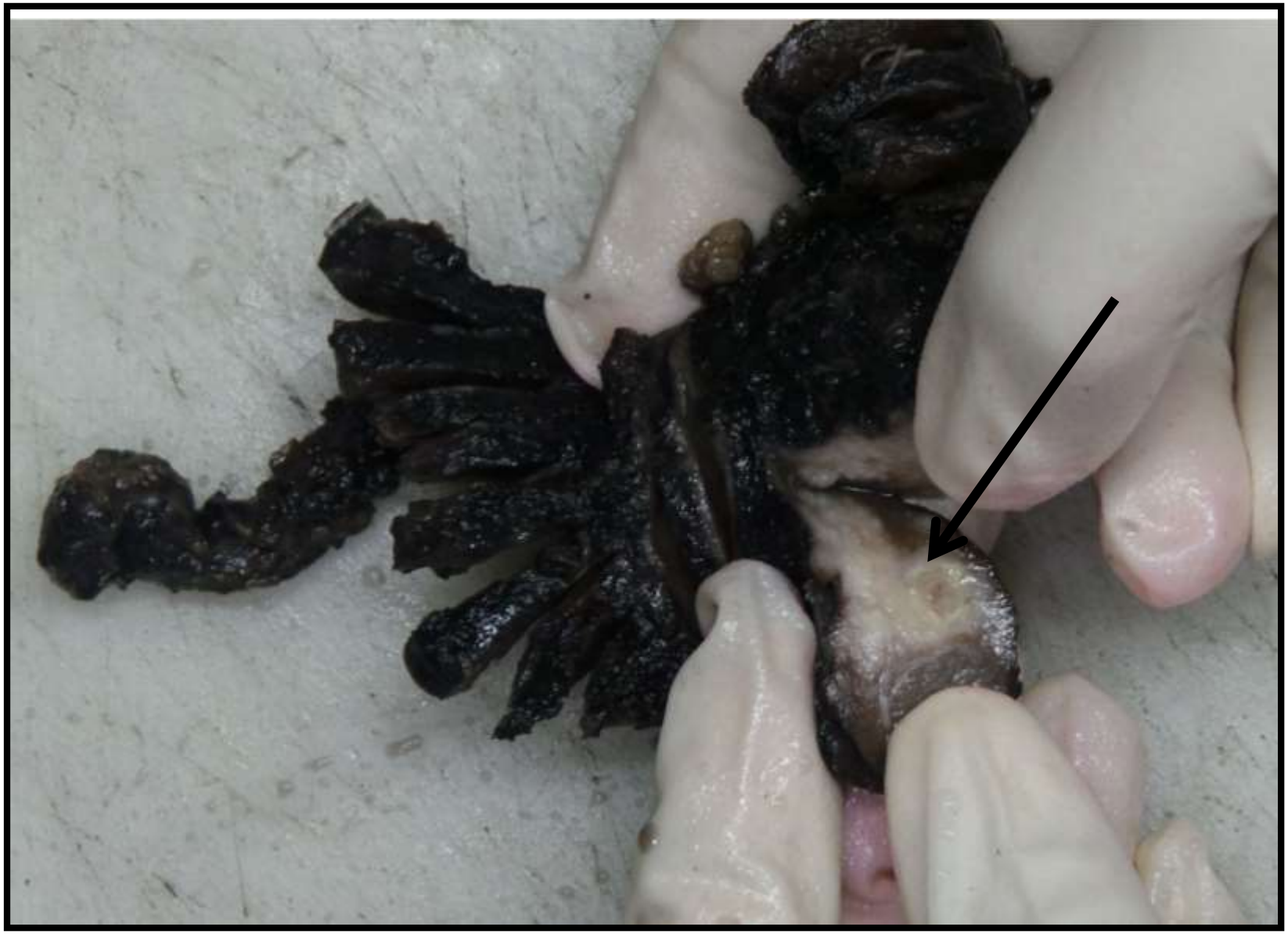

Left Lobe

Left Lobe Lesion: PTC

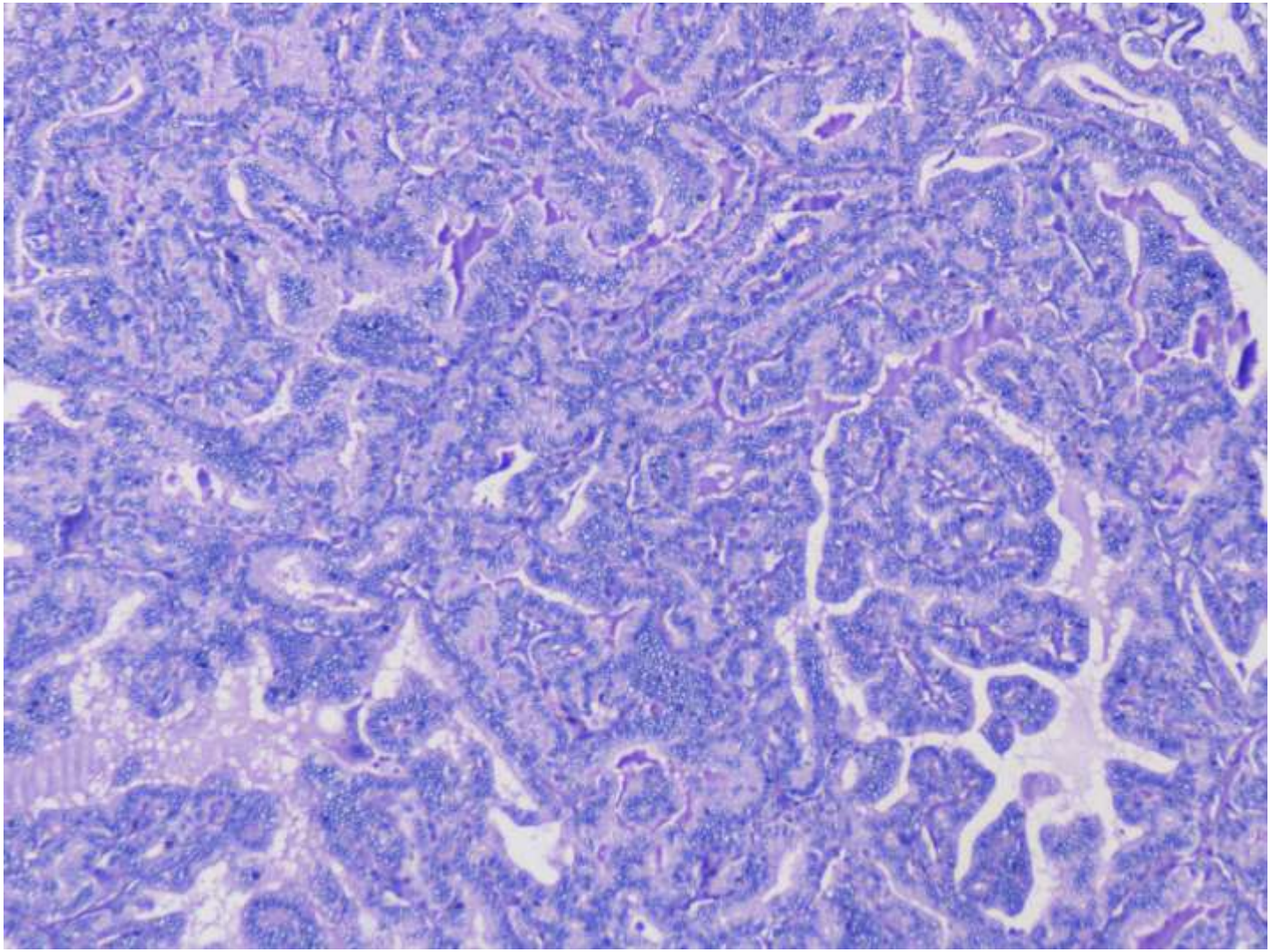

Right Lobe Lesion: PTC

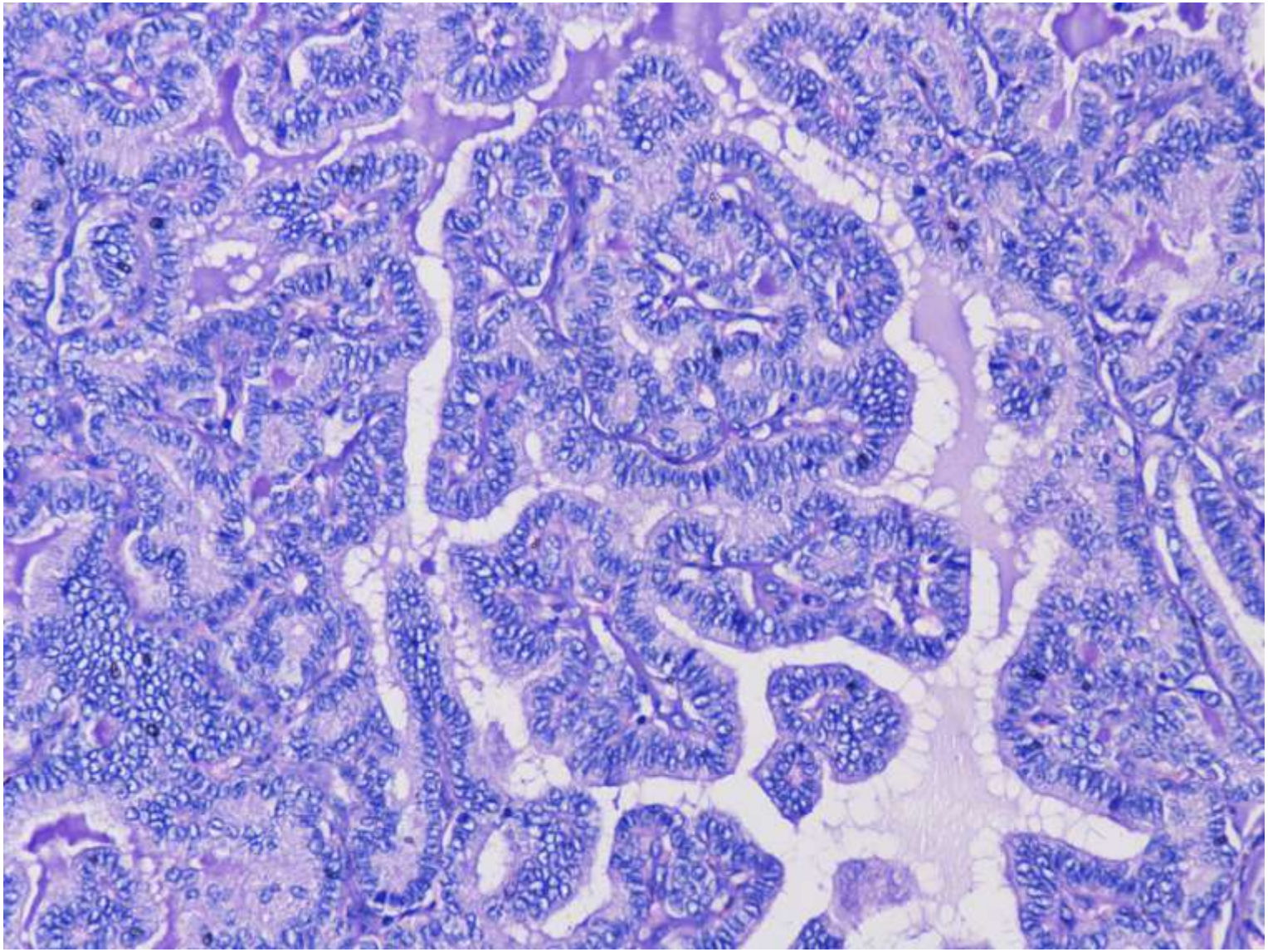

Final Diagnosis

- Multifocal Papillary thyroid carcinoma (mpT_2N_{1b}) involving both lobes of thyroid

BRAF (V600E): Positive

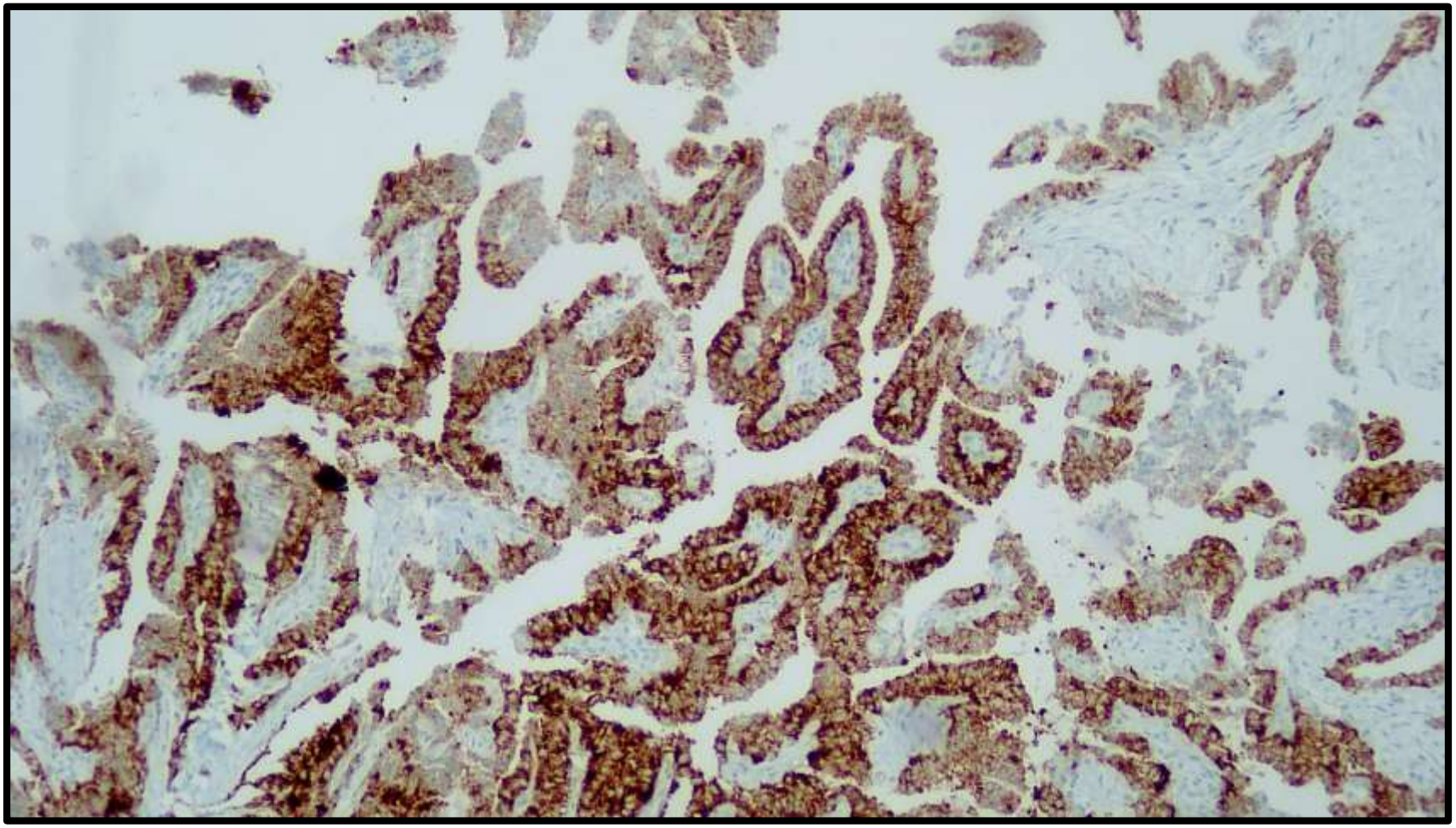

Discussion and Conclusion

- Papillary thyroid carcinoma (PTC) is the most common thyroid cancer which commonly presents with thyroid lump and regional lymphadenopathy, and rarely shows systemic distant metastasis on presentation.

- Metastatic involvement of lung and pleura has been described in the literature in an already diagnosed case of PTC

- However, breathlessness & pleural effusion as upfront presenting symptoms revealing an occult primary in the thyroid is an extremely rare event

- This can prompt an erroneous diagnosis of Primary lung adenocarcinoma with unwarranted toxic chemotherapy and radiation exposure

- Diligent histomorphological assessment and judicious IHC panel helps in ruling out the differential diagnosis and establishing the definite diagnosis

- Discussion in multispeciality tumour board as and when required is of paramount importance in such cases to arrive at a definitive strategy for management.

Thank You