

# Rajiv Gandhi Cancer Institute and Research Centre

A Unit of Indraprastha Cancer Society  
Registered under "Societies Registration Act 1860"

# Grossing of Endometrial Tumors

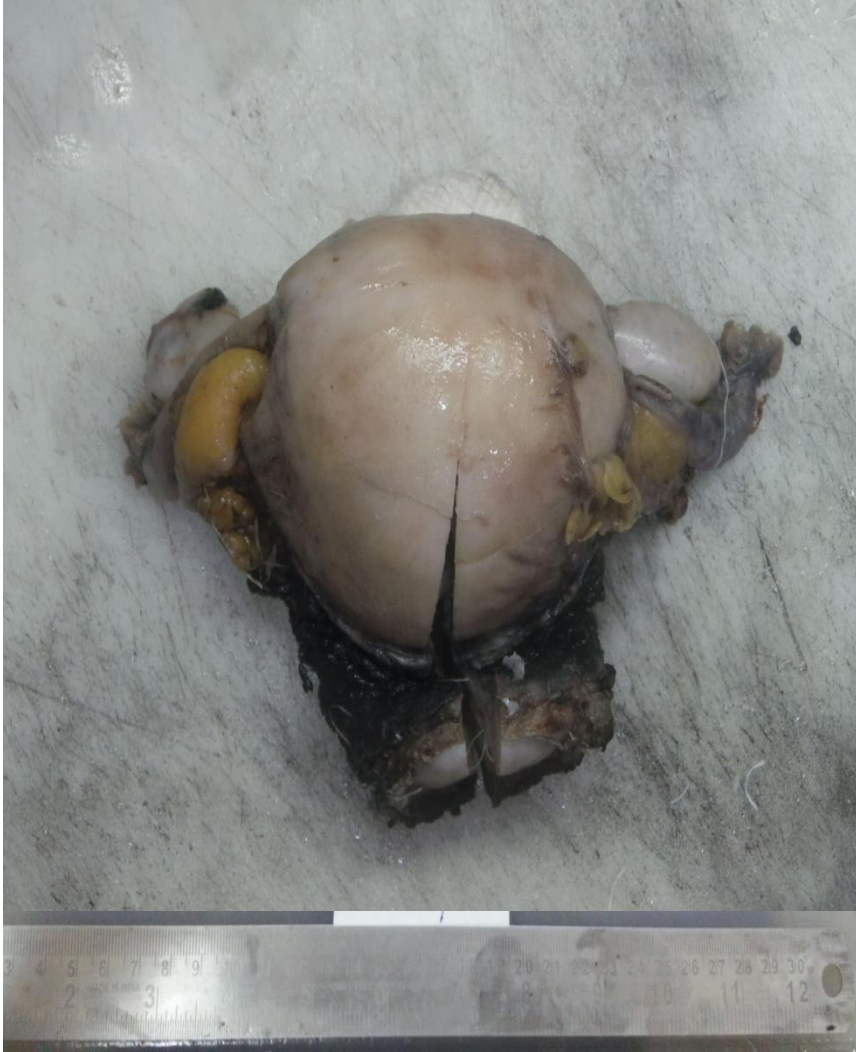Dr. Saloni Pahwa

- **Specimen type** :

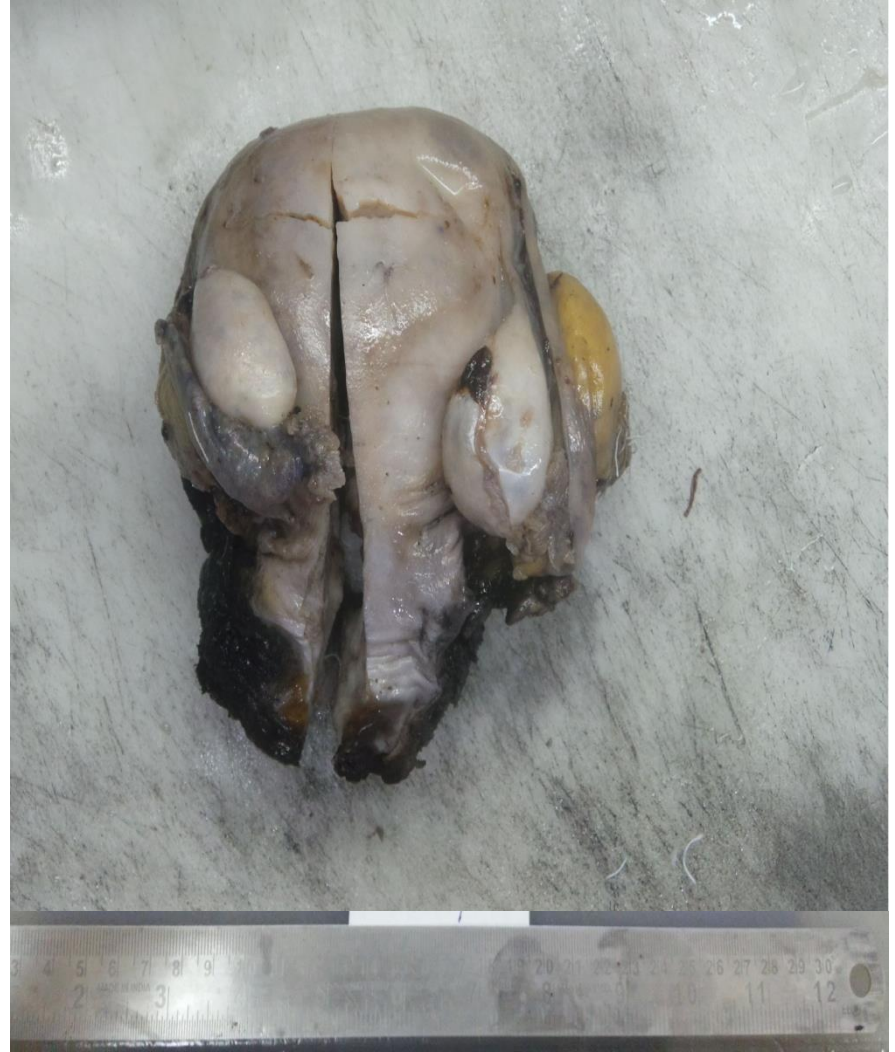1. Radical hysterectomy
2. Total hysterectomy and bilateral salpingo-oophorectomy

- **Handling** :

1. Identify anterior and posterior
- Ovaries (utero-ovarian ligament) are posterior to the round ligament
  - The anterior peritoneal reflection (bladder reflection) is higher than the posterior peritoneal reflection



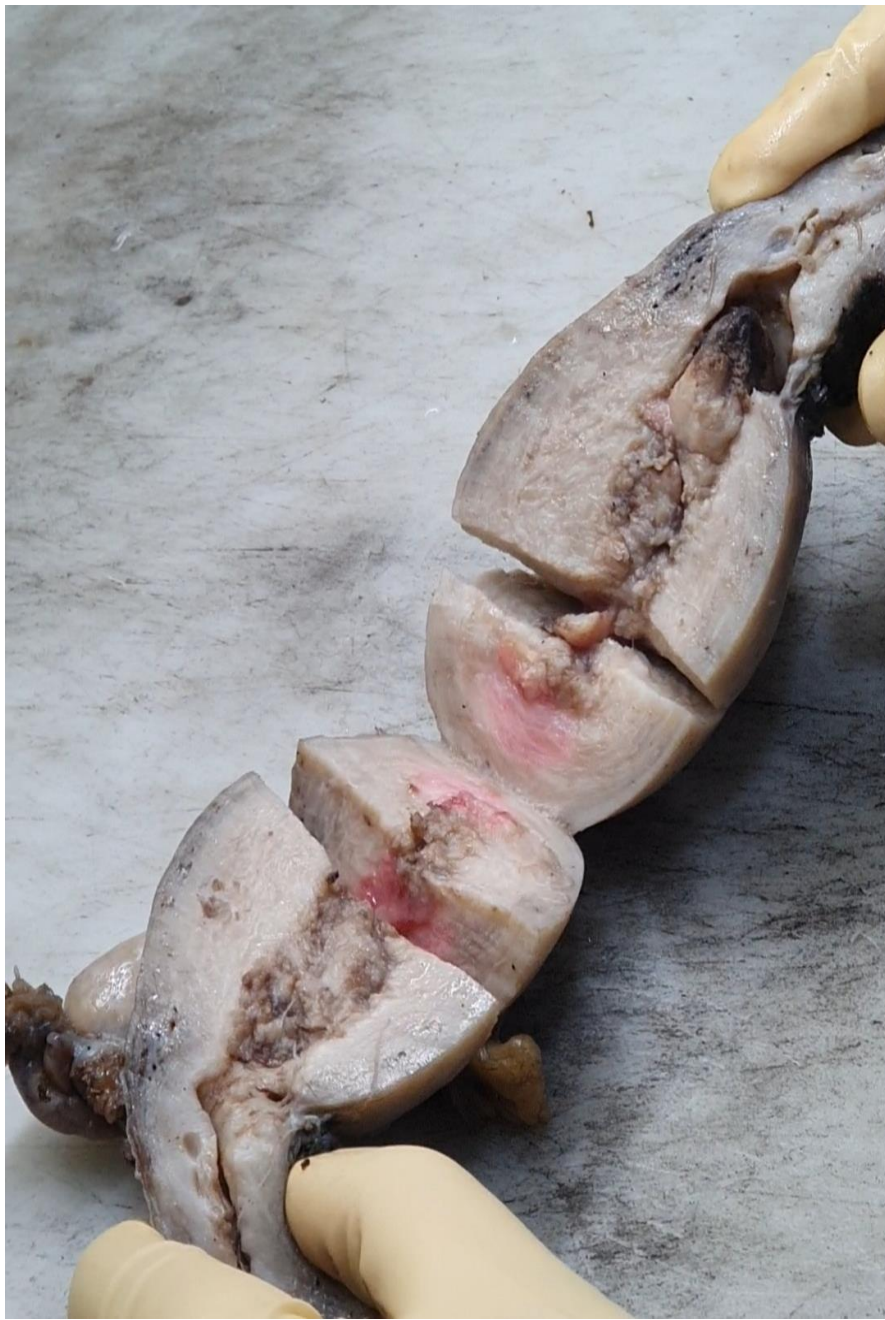**ANTERIOR**



**POSTERIOR**

2. Open the uterus along a probe using the endocervical and endometrial canal as a guide for incising in the proper tissue plane.

- The uterus should be opened along the lateral uterine walls (3 and 9 o'clock).
- The above method provides maximum exposure of the endometrial surface in a flat plane which allows better visualization and measurement of the tumor



# Gross Template

## Measurements

1. Weight of the specimen
2. Measurement of uterus with cervix : \_ \* \_ \*
3. Length of endocervical canal
4. Endometrial cavity measures \_cm
5. Average endometrial thickness : \_cm
6. Myometrial thickness ranges from \_\_\_ to \_\_\_ cm
7. Measurement of right and left ovary
8. Measurement of right and left fallopian tube

- **Serosa** : Pink/smooth/unremarkable/adhesions

- **Endometrium**

1. Lesion location : fundus/cornu/LUS/anterior wall/posterior wall
2. Size
3. Color/consistency
4. Configuration : solid/papillary/exophytic/polypoid
5. Myometrial involvement : present/absent
6. Depth of invasion : less than/greater than 50%
7. **Gross assessment of depth : Endomyometrial junction to the deepest point of invasion**
8. Lower uterine segment involvement : present/absent

- **Myometrium**

1. Leiomyoma : subserosal/intramural/submucosal
2. Size
3. Cut surface : nodular/calcification/necrosis/hameorrhage
4. Trabeculations/cysts

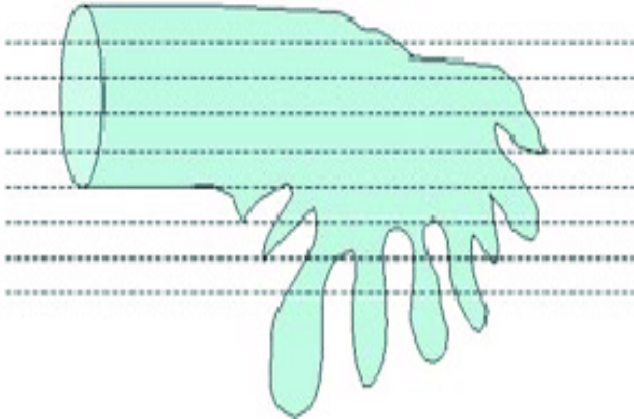

- **Cervix** : unremarkable/ulcer/erosion

- **Right and left ovary** : unremarkable/atrophic changes/lesions

- **Right and left FT** : unremarkable/adhesions/prior tubal ligation







## Sections To Be Submitted

- Full thickness sections from anterior and posterior uterine wall
- 1 section from uterine fundus
- Tumour with relationship to unremarkable endometrium
- LUS sections : 12' , 3' , 6' , 9'o clock
- Cervix : 12' , 3' , 6' , 9'o clock
- Vaginal cuff sections
- Entirely submit both the ovaries
- 2 cross sections of FT and fimbrial end
- Shave and submit right and left parametrial margins

**THANK YOU**